



PATIENT

Leo Gittles

SPECIES

Canine

BREED

Westie

SEX

MN

AGE

2006

WEIGHT

23lbs

INTERPRETED BY

Maggie Machen
Lamy, DVM, DACVIM
(Cardiology)

HOSPITAL NAME

Greenbrier Veterinary
Clinic

REFERRING VET

Dr. Boccanfuso

INVOICE

21432

DATE

10/8/21

PRESENTING CLINICAL SIGNS

History: History of ongoing cough, worsening recently, recent exam pet has soft crackles bilaterally, questionable grade 1 murmur, heart appears significantly enlarged on radiographs and there is possible mass effect/heart base tumor.

-Pertinent abnormal PE/Chem/CBC/UA Results: Neutrophilia, remainder NSF.

-Current medications: Meclizine 2.5mg (2 tabs SID,) Salix 12.5mg (1 tab BID,) Amoxi 125 (1 tab BID,) and medicated shampoo.

-Sedation used: Sedation not necessary.

-STAT: Not requested.

RADIOGRAPHIC FINDINGS *NOTE: Images submitted for supplemental information only.

Normal overall cardiac dimension, possible right-sided cardiomegaly. No obvious evidence of CHF.

ECHOCARDIOGRAM FINDINGS

2D, m-mode, color flow and doppler imaging is available. Mild thickening of mitral valve leaflets with no obvious prolapse into the left atrial lumen. Trace mitral regurgitation with a normal left atrial dimension. Normal LV diameter with adequate myocardial function. The tricuspid valve appears mildly thickened, and there is moderate tricuspid regurgitation. Mild right atrial enlargement; mild right ventricular hypertrophy with mild dilation consistent with pulmonary arterial hypertension. TR velocity consistent with a PG of 50mmHg (normal <25). The pulmonic and aortic valves are normal in morphology and mobility. Mild main PA and branch dilation. No obvious pulmonic insufficiency. Normal pulmonic and aortic outflow velocities. No pericardial or pleural effusion noted. No cardiac tumors observed.

CARDIAC CHART

CANINE CARDIAC PARAMETERS	MR VMAX (m/s)	TR VMAX (m/s)	LA/AO (Boon method)	LA/AO (Heart Base; Swe)	FS (%)	EF (%)	EPSS (cm)
NORMAL PARAMETER	4.5-5.5	<2.7	1.3	<1.6	28-40	40-100	<0.6
PATIENT	NM	3.5	NM	1.3	50	82	NM
CANINE CARDIAC PARAMETERS	HR (BPM)	AV VMAX (m/s)	PV MAX (m/s)	BODY WEIGHT (kg)	LA 2D short axis Base view (cm)	LVIDd Avg; 2D and m-mode short axis (cm)	LVIDs Avg; 2D and m-mode short axis (cm)
NORMAL PARAMETER	50-100	0.7-1.7	0.7-1.6	BELOW	BELOW	BELOW	BELOW
PATIENT	60	0.9	0.97	10.4	2.0	3.1	1.6
*Normal chamber parameters expressed as a mean value (SD)				3	1.27 (5.3)	2.46 (2.46)	1.36 (5.5)
BODY WEIGHT DEPENDENT PARAMETERS				5	1.40 (4.5)	2.74 (5.2)	1.60 (4.7)
<i>*Note: All measurements based upon multi-modal images and methods. An average value is reported.</i>				10	1.50 (3.8)	3.27 (3.5)	2.06 (3.1)
				15	1.83 (2.0)	3.71 (2.4)	2.43 (2.1)
				20	2.02 (1.9)	4.14 (2.2)	2.80 (2.0)
				25	2.18 (2.4)	4.48 (2.9)	3.10 (2.5)
				30	2.33 (3.3)	4.83 (3.9)	3.39 (3.4)
				35	2.48 (4.3)	5.17 (5.0)	3.69 (4.5)
				40	2.62 (5.2)	5.48 (6.1)	3.96 (5.4)
				50	2.88 (7.1)	6.07 (8.3)	4.46 (7.4)

Adapted from June Boon, Veterinary Echocardiography, 1998
Rishniw M and Hollis NE, J Vet Intern Med 2000; 14:429-435
Hansson et al, Vet Rad and Ultrasound 2002
Bonagura et al. Echocardiography: principles of interpretation, Vet Clin North Am 15:1177, 1995

INTERPRETATION OF THE FINDINGS & FURTHER RECOMMENDATIONS

Pulmonary hypertension (PAH) is present, as evidenced by an enlarged right heart, dilated MPA and elevated TR velocity. The estimated systolic pulmonary arterial pressure is 50-60mmHg, with normal being <25mmHg. This is causing pressure overload of the right ventricle. Mild MR is noted; however, the left heart is normal in size indicating low risk for complication such as left-sided CHF. No obvious heart-based masses are appreciated; however, it is important to note that small tumors are easily missed. Advanced imaging may be necessary should clinical suspicion persist. No additional issues are identified.

Clinical signs of weakness, heavy breathing, cyanosis, and syncope are attributed to severe PAH. The underlying genesis of PAH is poorly understood in cases other than heartworm infestation, though it occurs with increased frequency in a variety of forms of chronic lung disease and in patients with idiopathic pulmonary fibrosis. This breed is highly predisposed to IPF which is suspected in this case. Consider full Radiologist review of the films for a more thorough pulmonary evaluation. If not performed, a heartworm antigen test is recommended. Given the chronicity of the disease seen here, COPD/chronic bronchitis and/or primary PF as an underlying cause with an acute secondary exacerbating insult (infectious or inflammatory) is suspected. Patients with this degree of PAH and pulmonary disease can develop right-sided congestive heart failure (ascites), debilitating cyanosis, labored breathing and exertional syncope if poorly controlled.

Given the recent history of respiratory signs, the most common cause is an infectious or inflammatory insult causing a decline in already poor oxygenation status. A PTE cannot be ruled out. Coverage with broad spectrum pulmonary antibiotic (fluoroquinolone) is recommended, in addition to vasodilation using pimobendan and sildenafil. I would discontinue Lasix as diuretics can actually further reduce preload in cases of debilitating PAH and worsen clinical signs. Depending on patient stability, hospitalization for oxygen support, fluid therapy and IV antibiotics may be necessary.

Once stable, use of theophylline and/or taper course of anti-inflammatory steroids can also be beneficial in these cases, to treat exertional dyspnea or acute flare ups and decrease the inflammatory component as much as possible. PRN use of cough suppressants may also be beneficial. Unfortunately, the prognosis overall is poor, however I am hopeful we can provide some medical relief going forward.

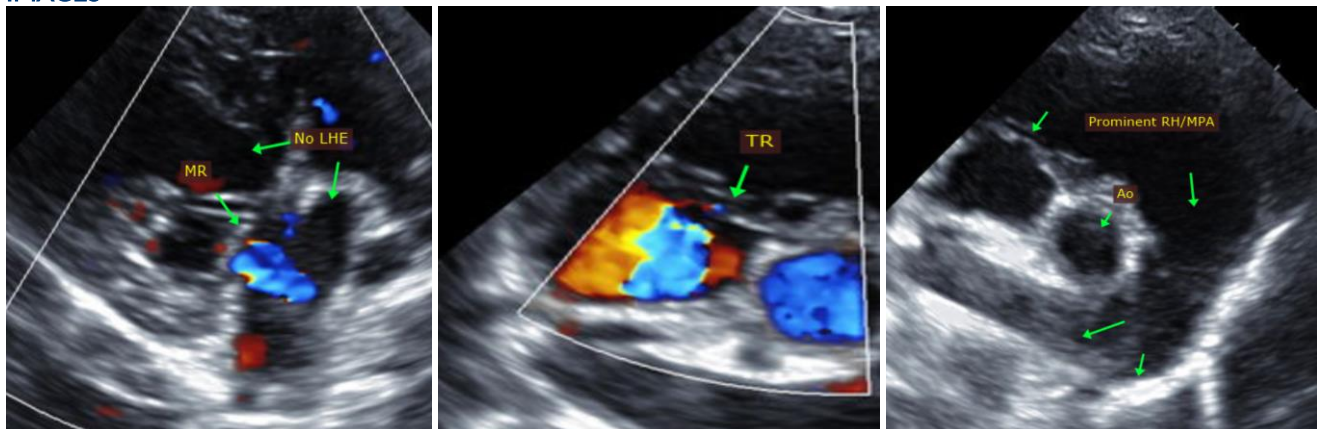
Omega fatty acid supplementation (anti-inflammatory) may be of some long-term benefit. Monitor for worsening of labored breathing, exercise intolerance or collapse episodes.

PLAN:

Consider submit CXR for Radiologist review in light of echo findings. Discontinue diuretic. Consider hospitalization for fluid therapy, O2 support if needed. Institute course of pulmonary antibiotics (Enrofloxacin or similar) IV or PO depending on patient stability. Institute sildenafil (Viagra) 1-2mg/kg PO q8h. Institute Pimobendan 0.2-0.3mg/kg PO q12h. Can also use hydrocodone, taper course of steroids, and/or theophylline depending on chronic clinical signs of cough/exertional dyspnea.

Recommend recheck echocardiogram in 4-6 months to reassess pulmonary pressures, sooner if any development of clinical signs.

IMAGES



The information and recommendations provided are based on the images presented by the referring veterinarian. No evaluation can be communicated regarding pathology that was not visible in the image/video clips provided.

Thank you for this referral. This report was generated using transcription software, and minor dictation errors may be present. If the clinical or image interpretation does not parallel your findings or if I can be of any further assistance, please contact me.

Maggie Machen Lamy, DVM
Diplomate of the American College of Veterinary Internal Medicine (Cardiology)
info@sonopath.com